

Visual Atlas of Eye Bank Specular Microscopy – Donor Corneal Endothelium Imaging

Images courtesy of Mississippi Lions Eye Bank (Jackson, MS)¹, Lions Eye Bank of North Carolina (Winston-Salem, NC)² and SightLife (Seattle, WA)³

Compiled by HAI Laboratories, Inc. (Lexington, MA)

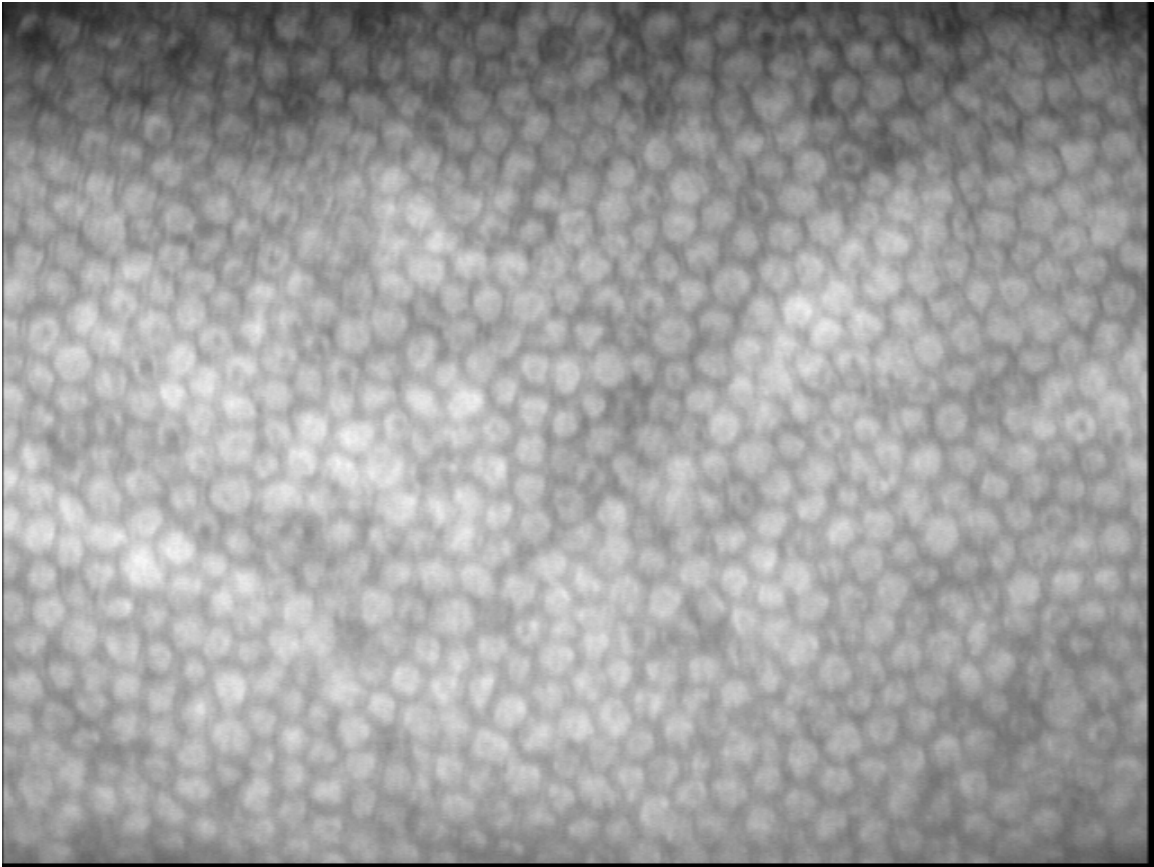
Contents	Page
1. High endothelial cell density.....	2
2. Average endothelial cell density.....	2
3. Low endothelial cell density.....	5
4. Vial distortion.....	6
5. Surface folds.....	7
6. Surface folds and cell loss.....	7
7. Stress line and bloodstains.....	7
8. Bloodstains.....	8
9. Mild polymegathism.....	9
10. Polymegathism.....	10
11. Polymegathism and pleomorphism.....	10
12. Snail tracks (forceps trauma).....	11
13. Corneal guttata.....	12
14. Early-stage dystrophy.....	13
15. Dystrophy.....	13
16. Severe dystrophy.....	14
17. Reverse cells (cause unknown).....	15
18. Post-cut cornea, mild folding.....	16
19. Post-cut cornea, mild swelling.....	17
20. Post-cut cornea.....	17

Images captured using:

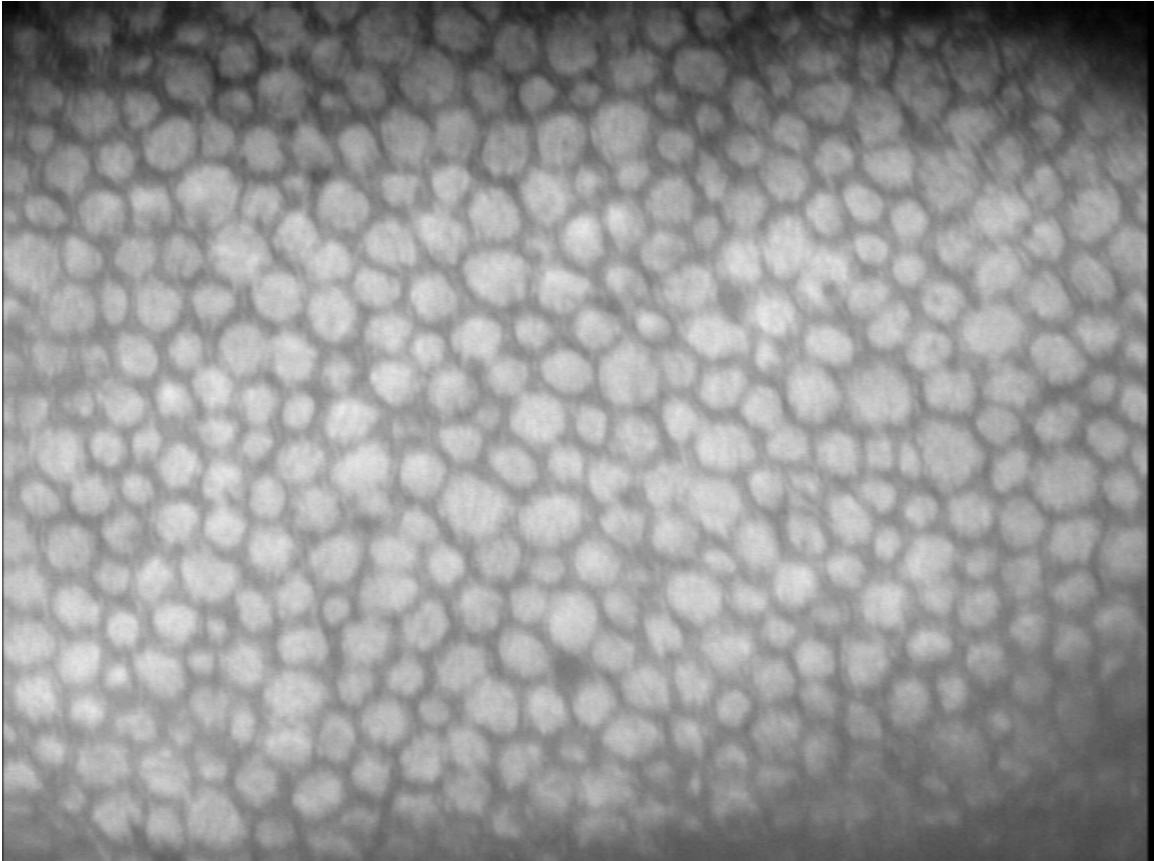
¹ HAI EB-3000xyz (Inverted) Eye Bank Specular Microscope

² HAI EB-2000xyz (Traditional) Eye Bank Specular Microscope

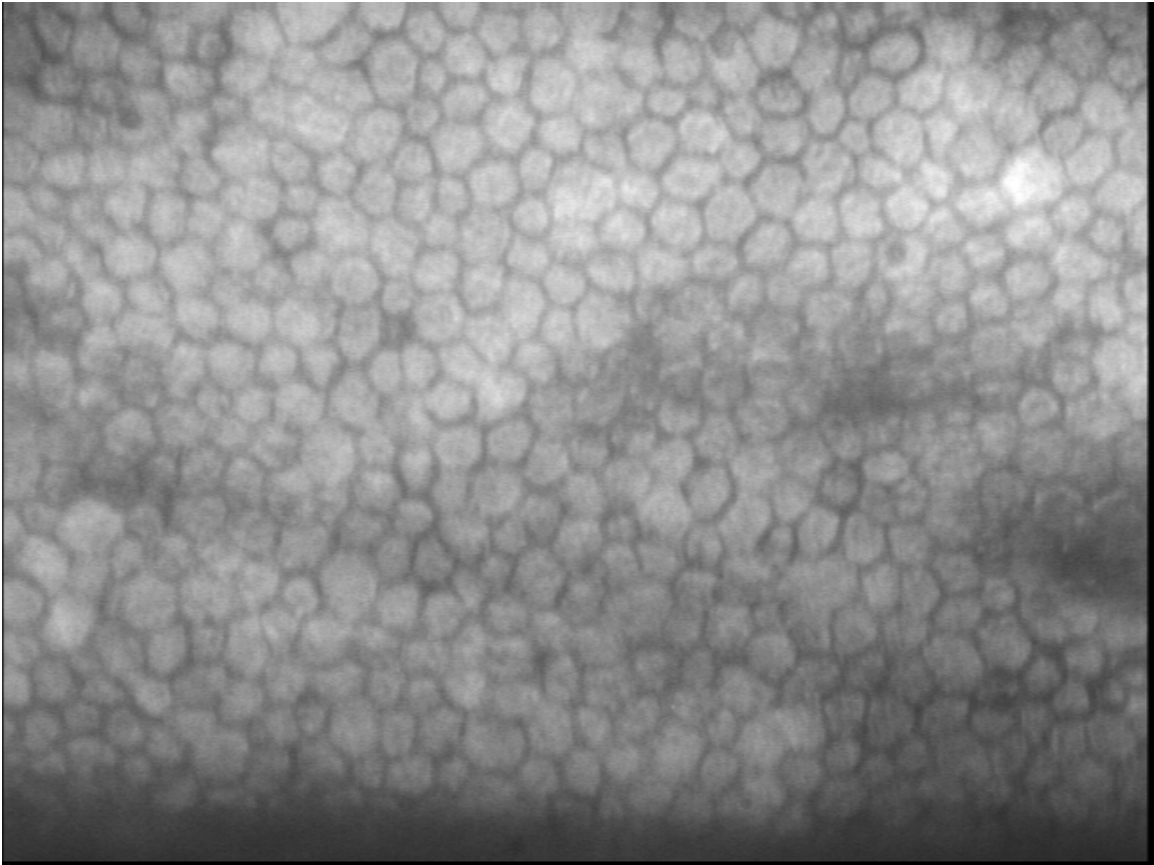
³ HAI EB-2000xyz and EB-3000xyz Eye Bank Specular Microscopes



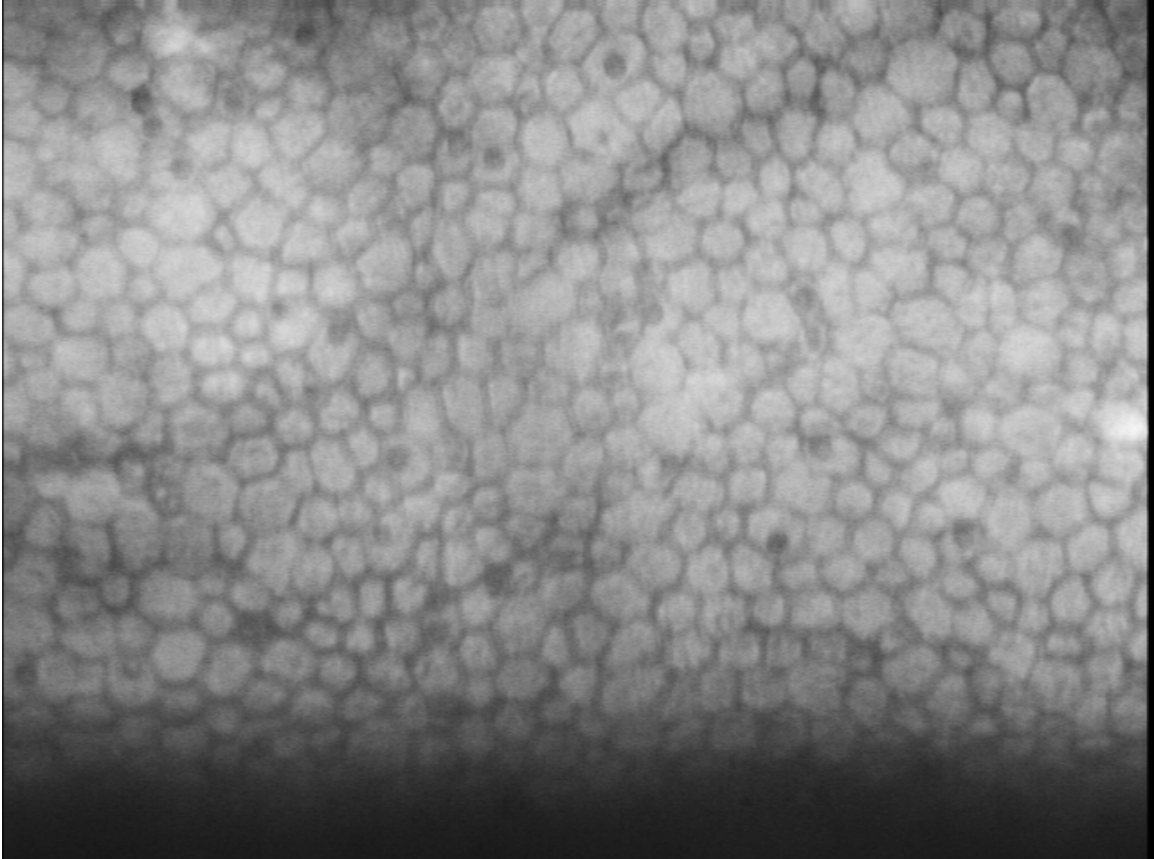
1. High endothelial cell density



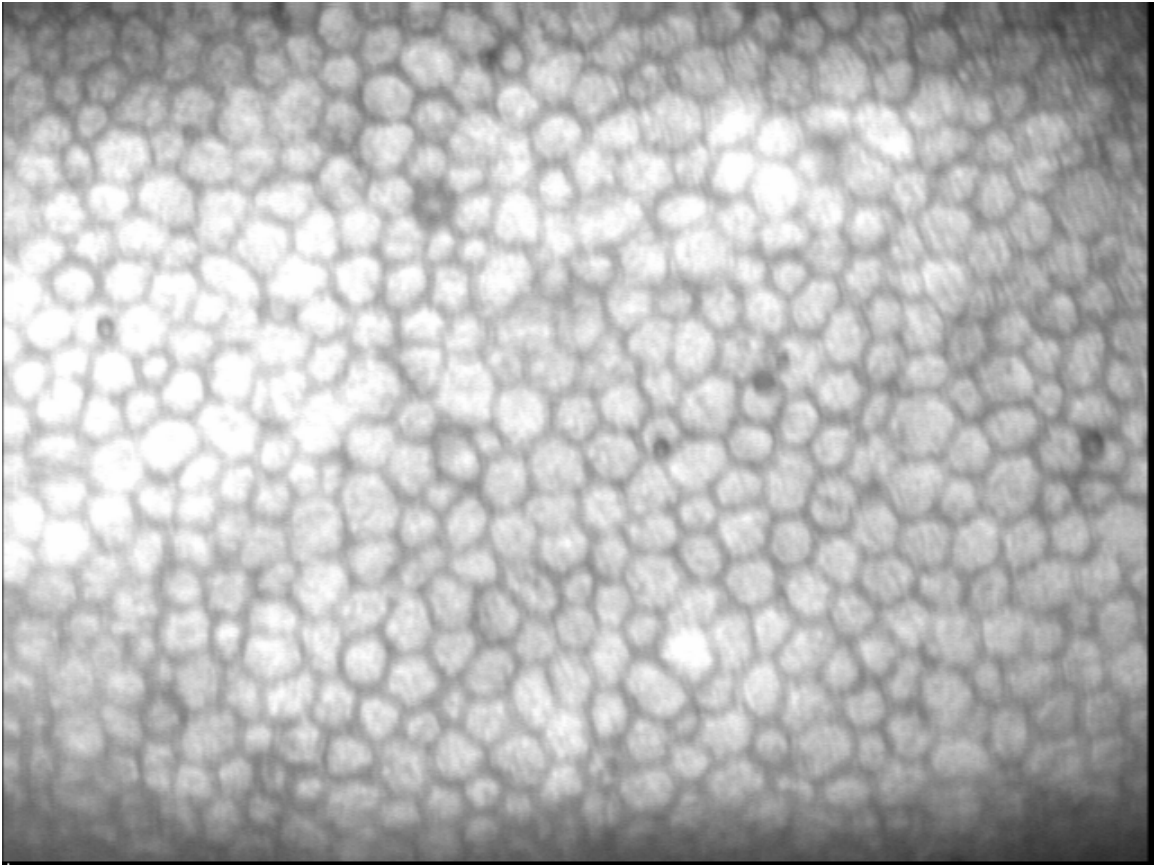
2a. Average endothelial cell density



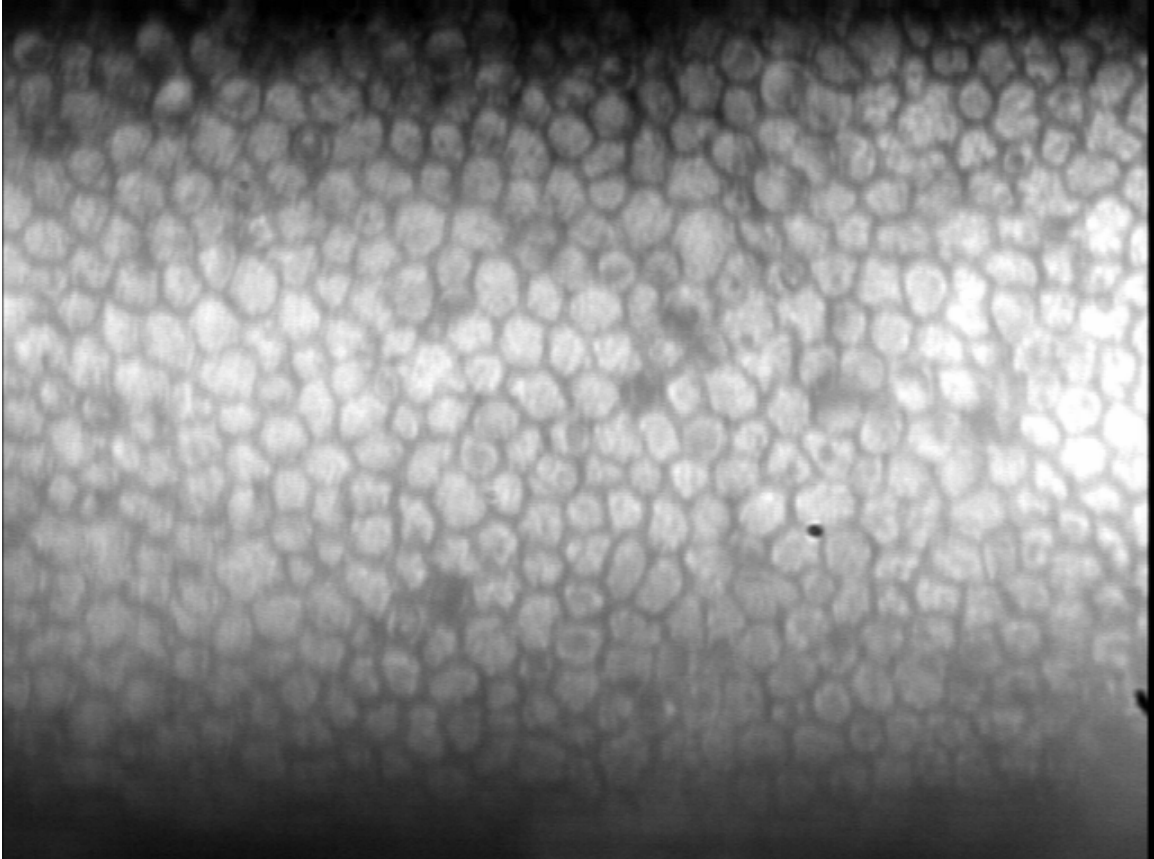
2b. Average endothelial cell density



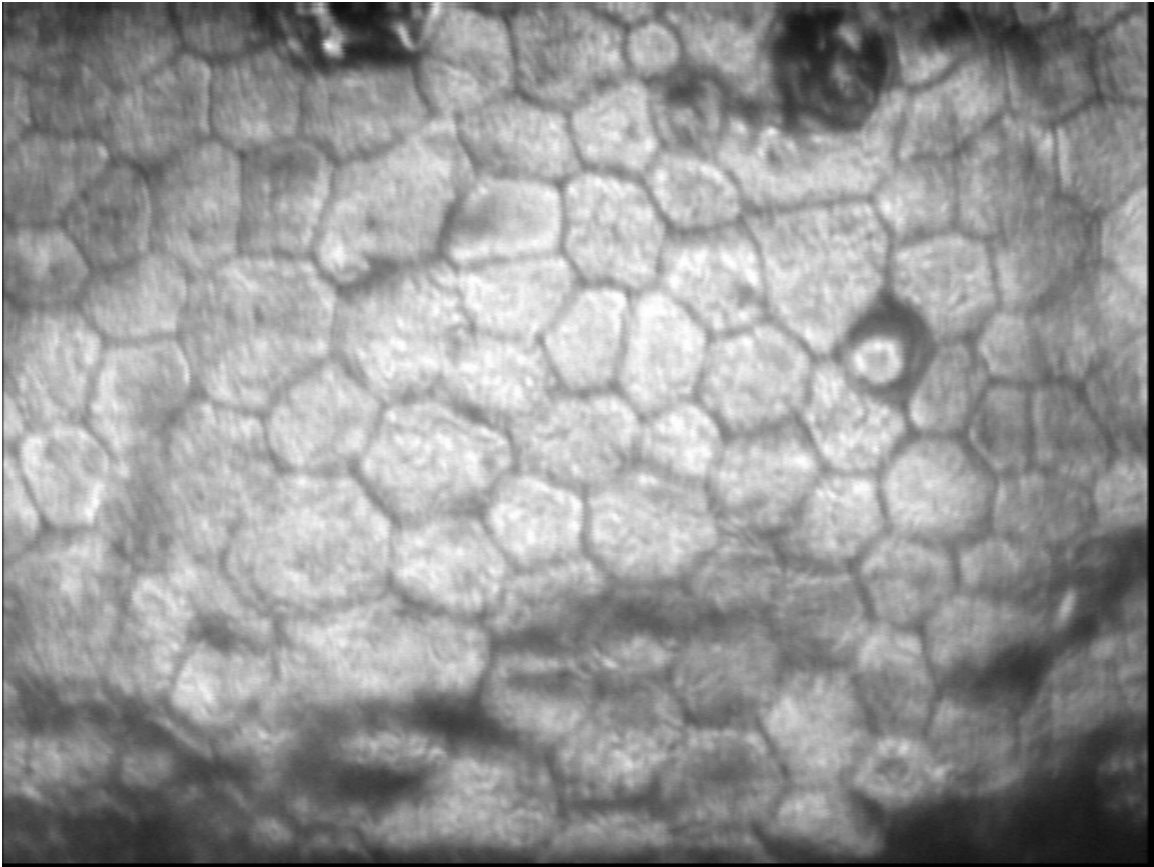
2c. Average endothelial cell density



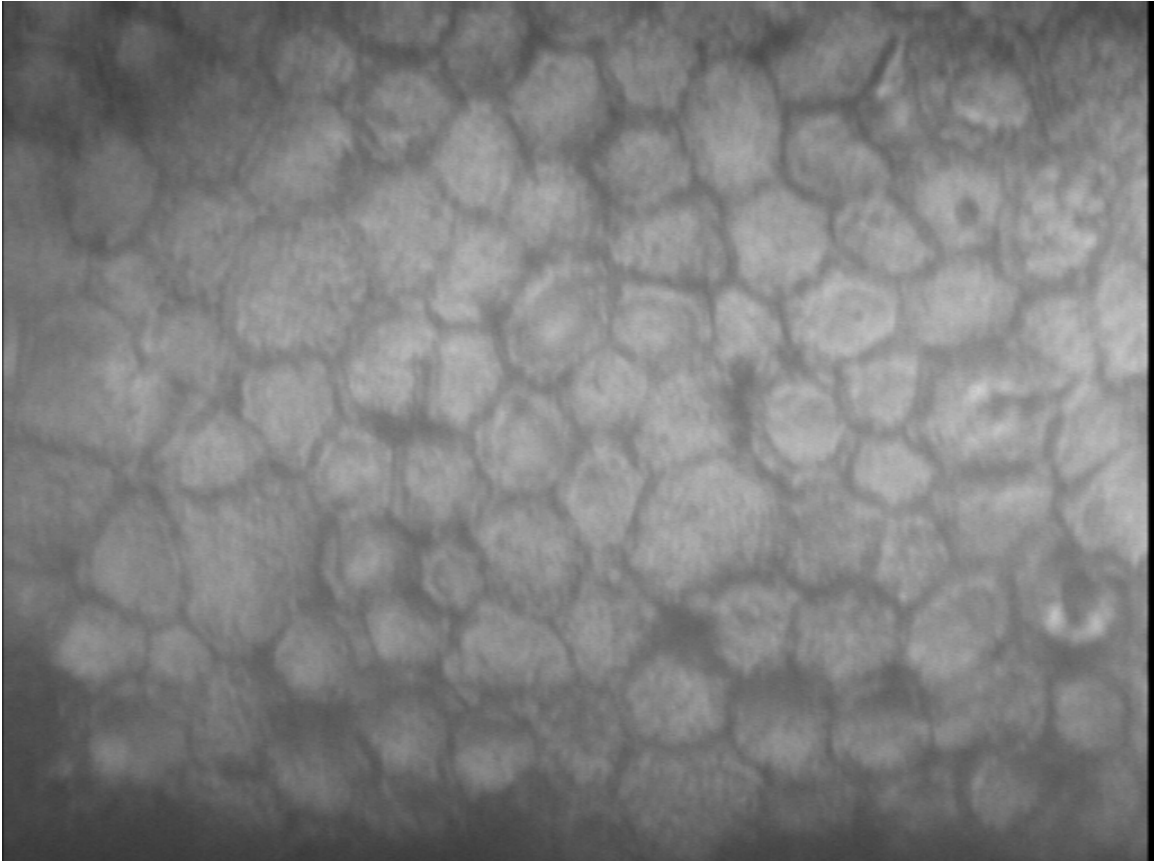
2d. Average endothelial cell density



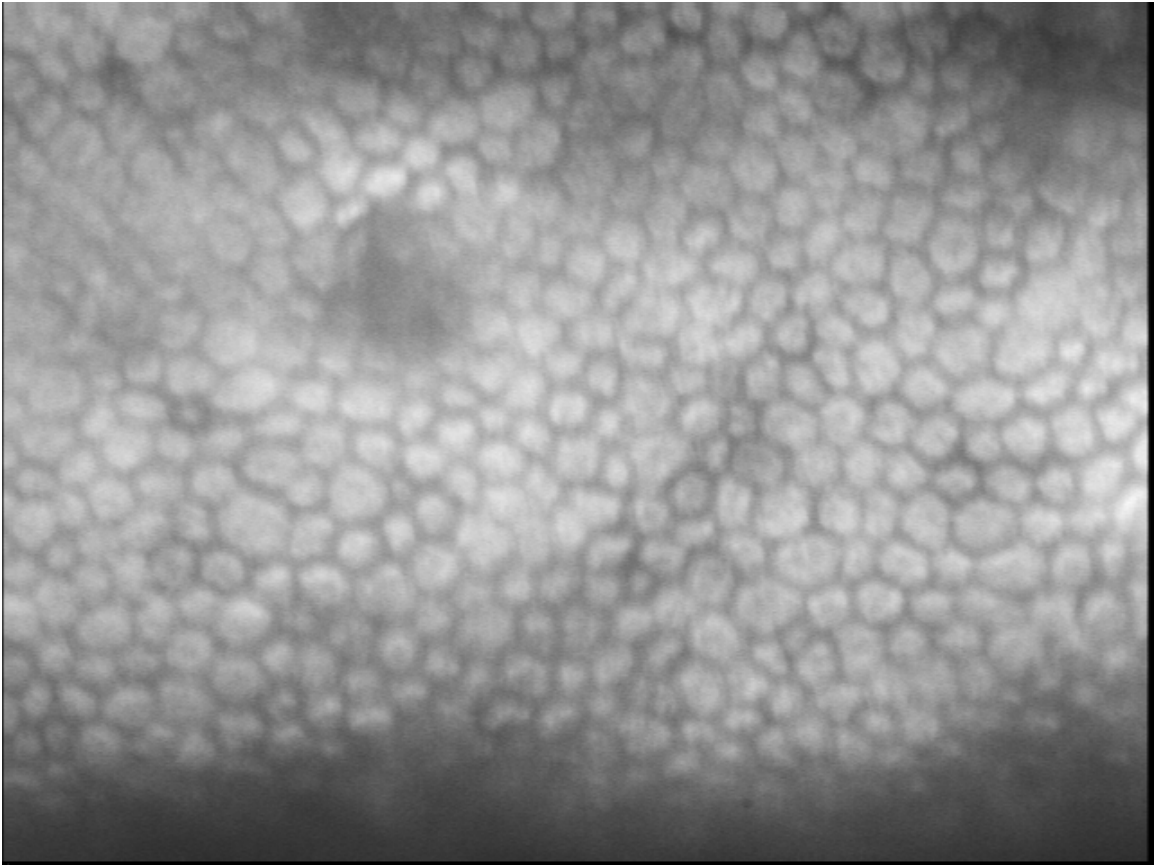
2e. Average endothelial cell density



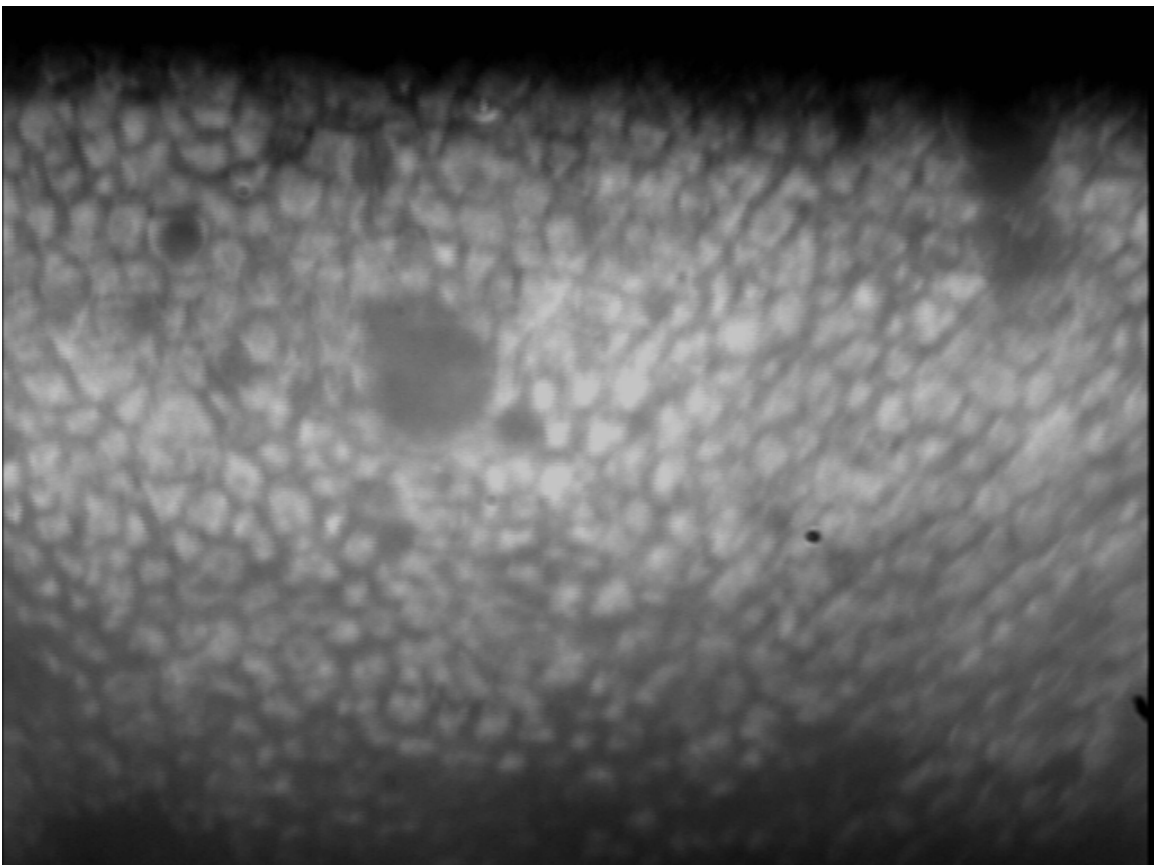
3a. Low endothelial cell density



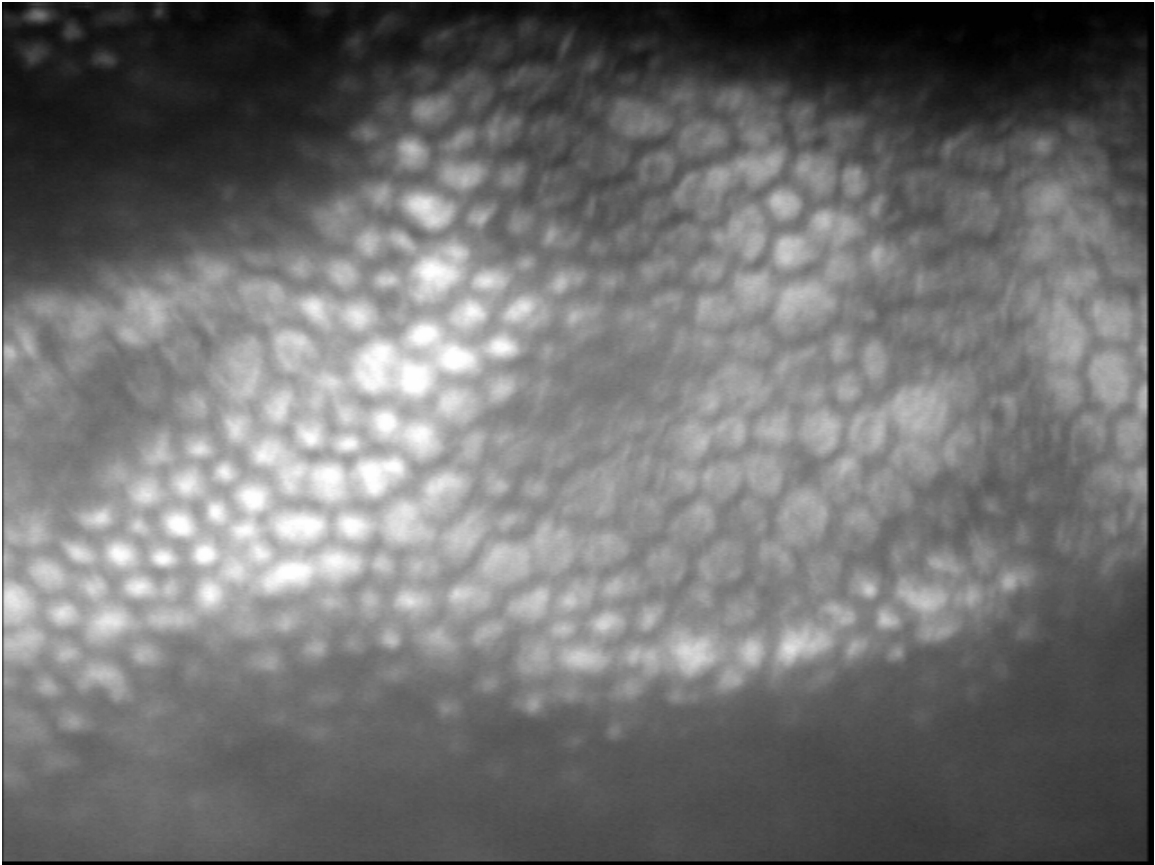
3b. Low endothelial cell density



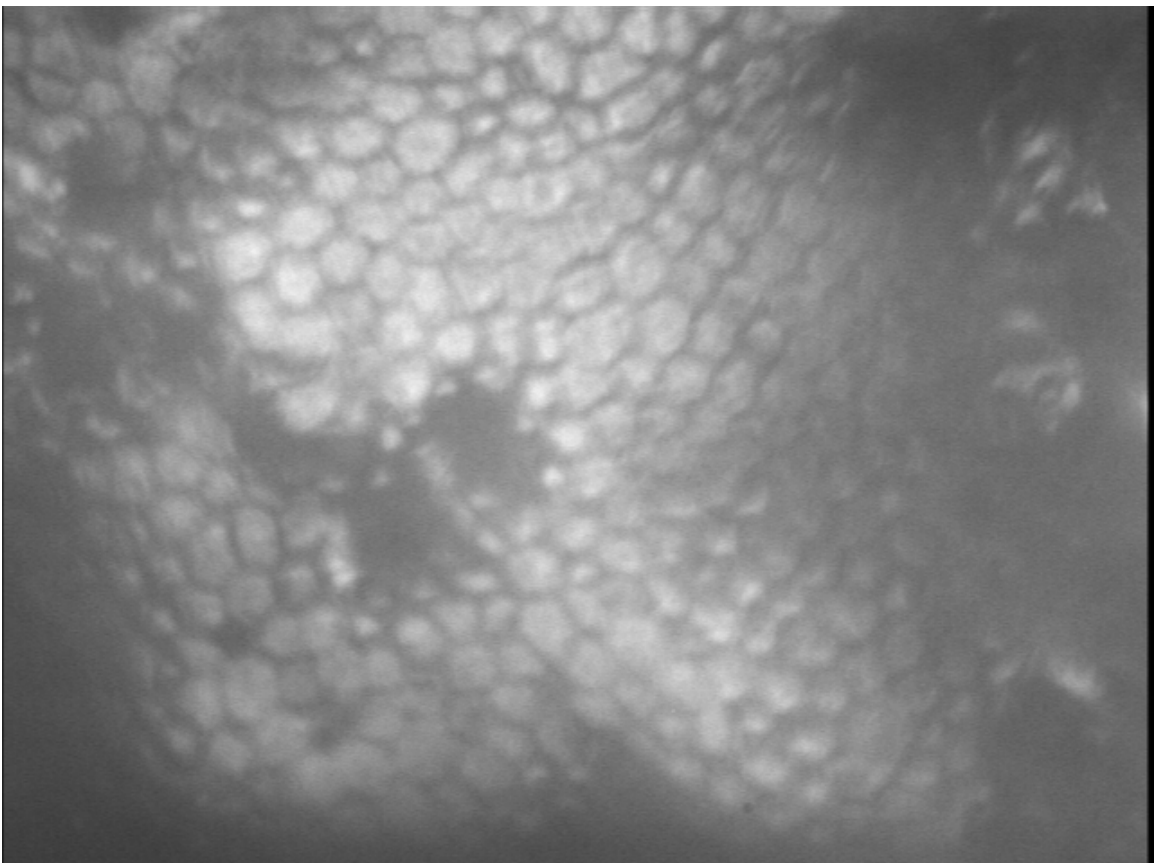
4a. Vial distortion (top left corner)



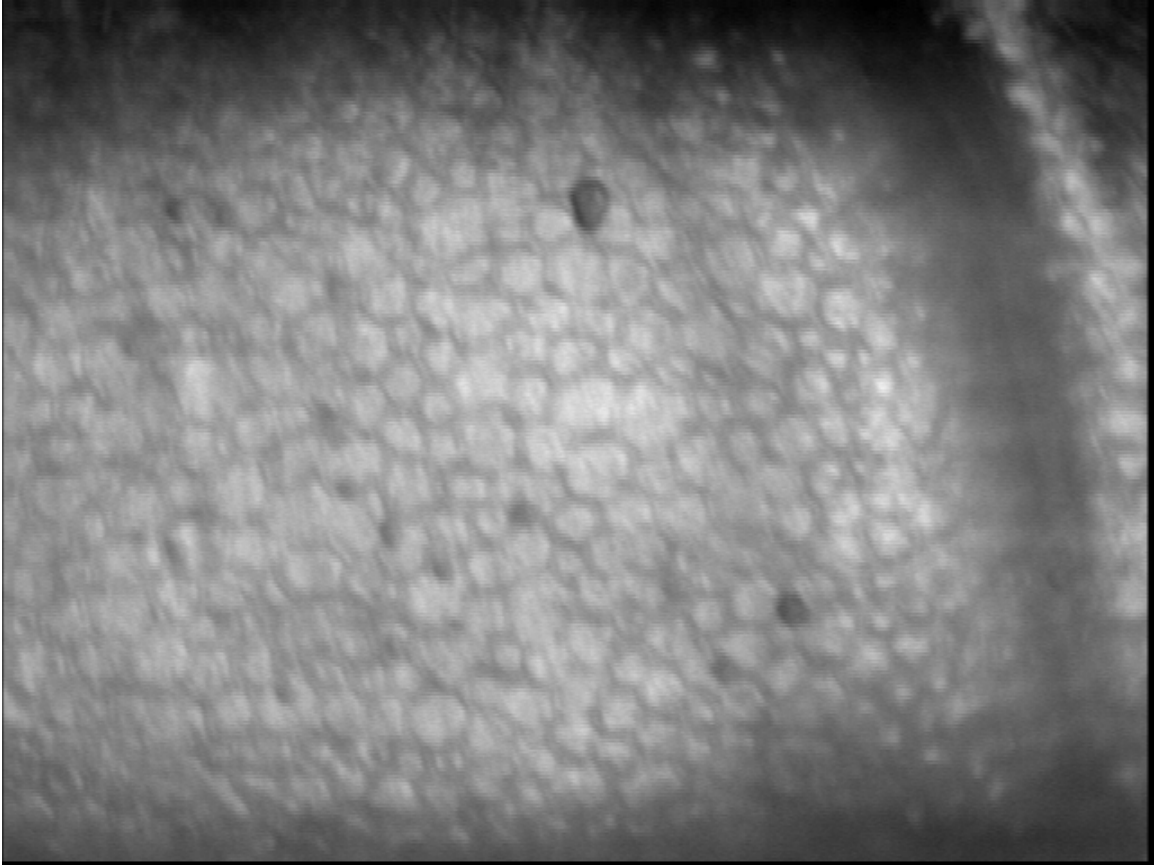
4b. Vial distortion (bottom right corner)



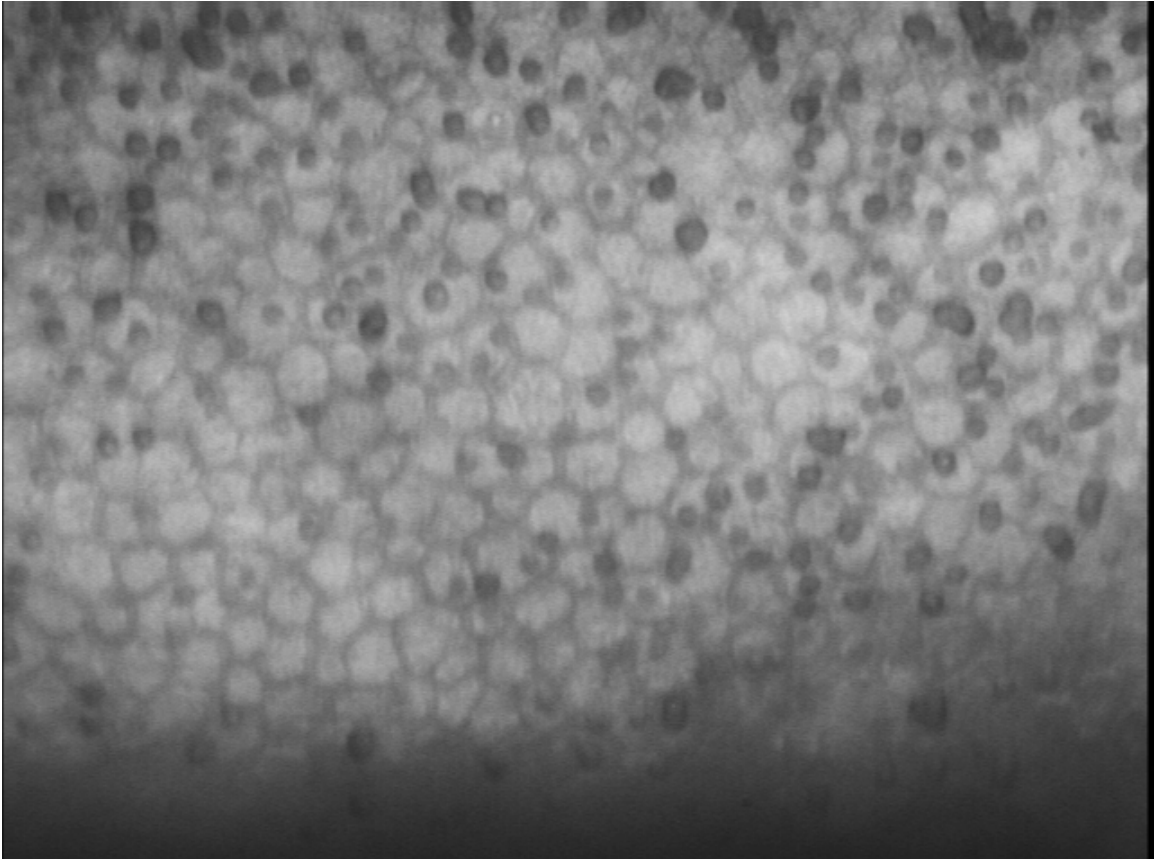
5. Surface folds



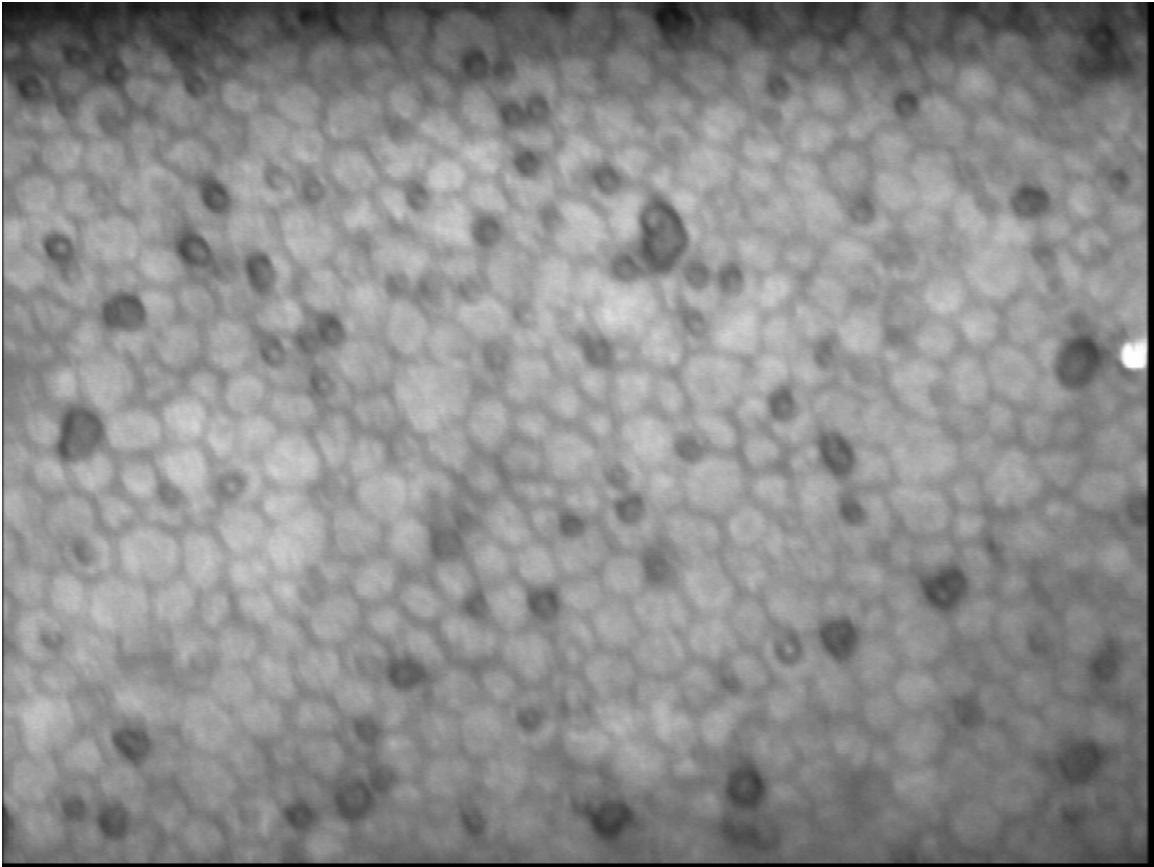
6. Surface folds and cell loss



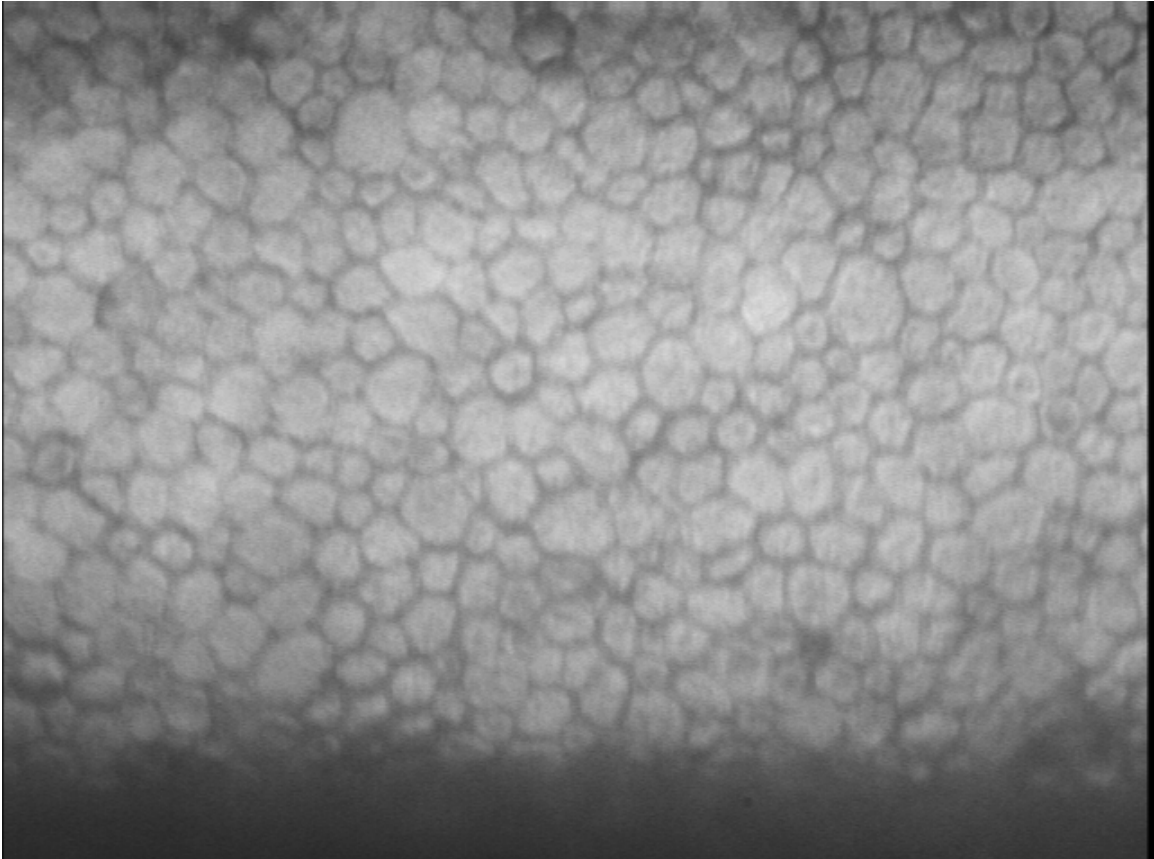
7. Stress line (right) and bloodstains (center)



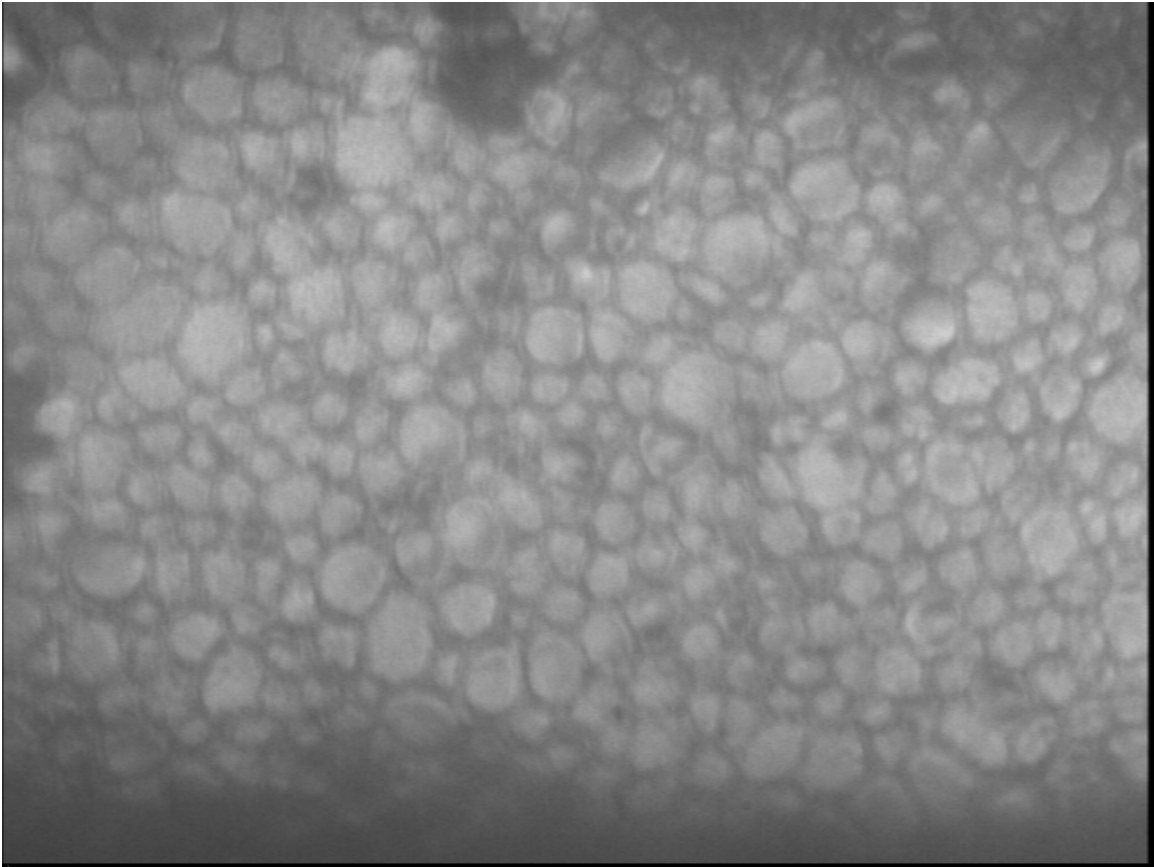
8a. Bloodstains



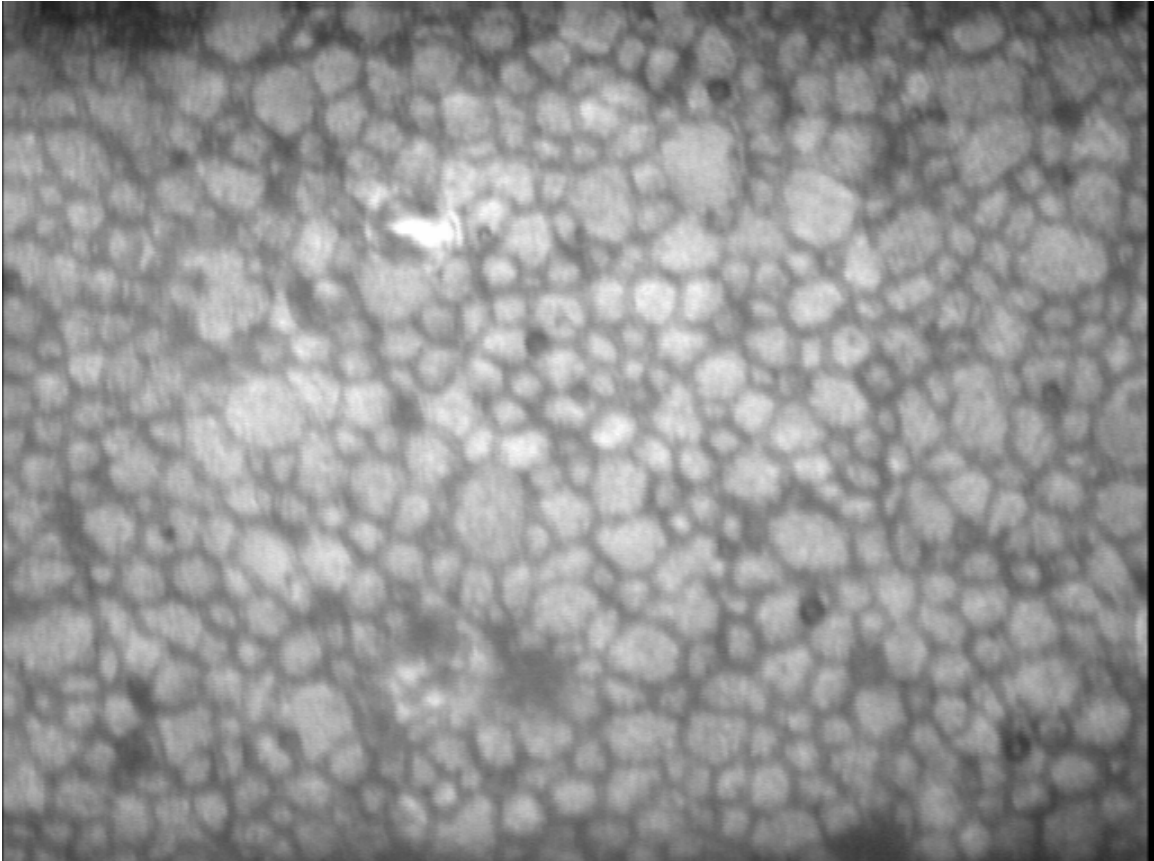
8b. Bloodstains




9. Mild polymegathism



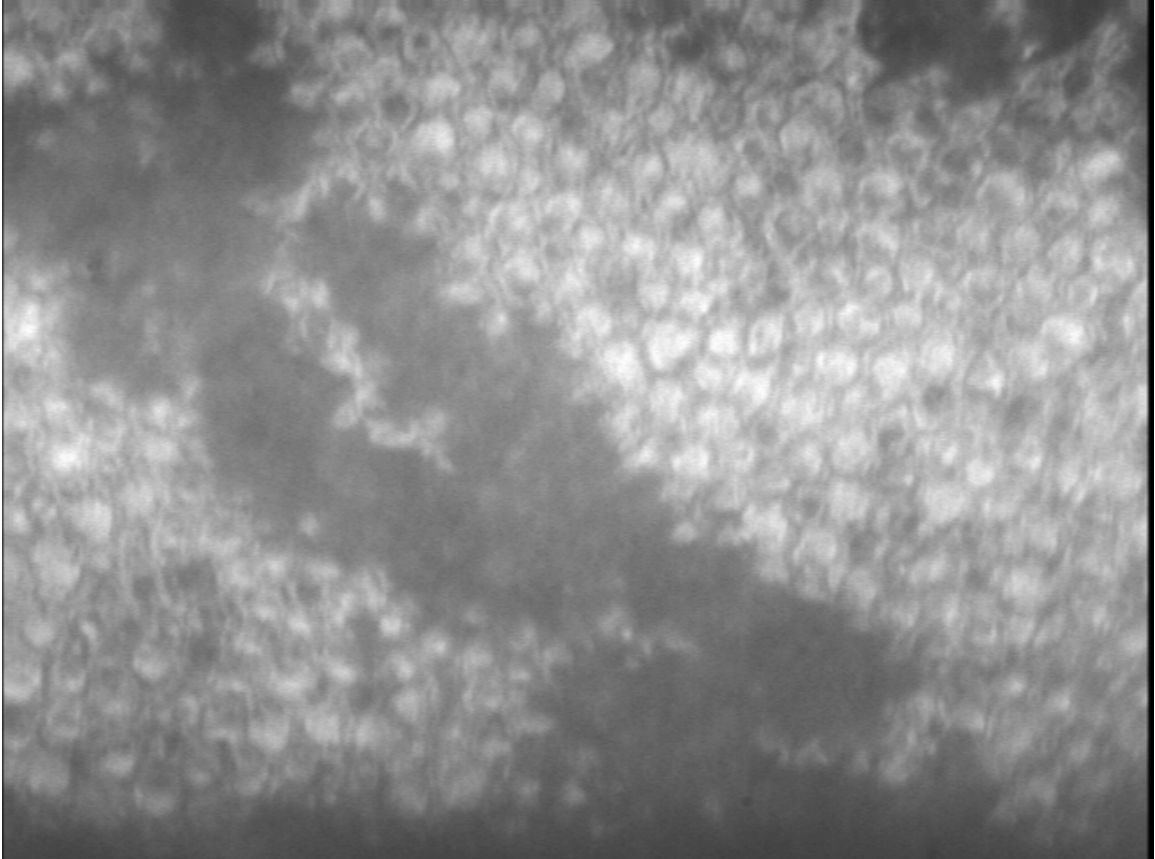
10. Polymegathism



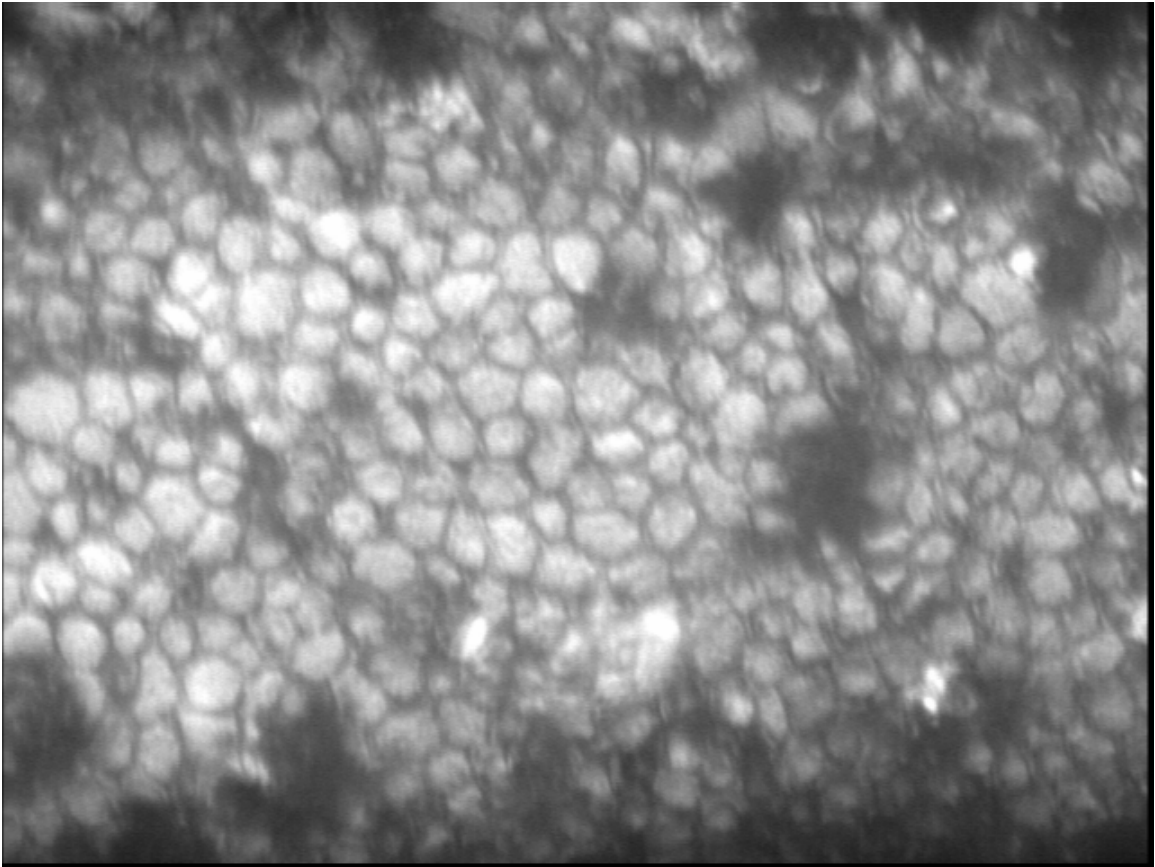
11. Polymegathism and pleomorphism



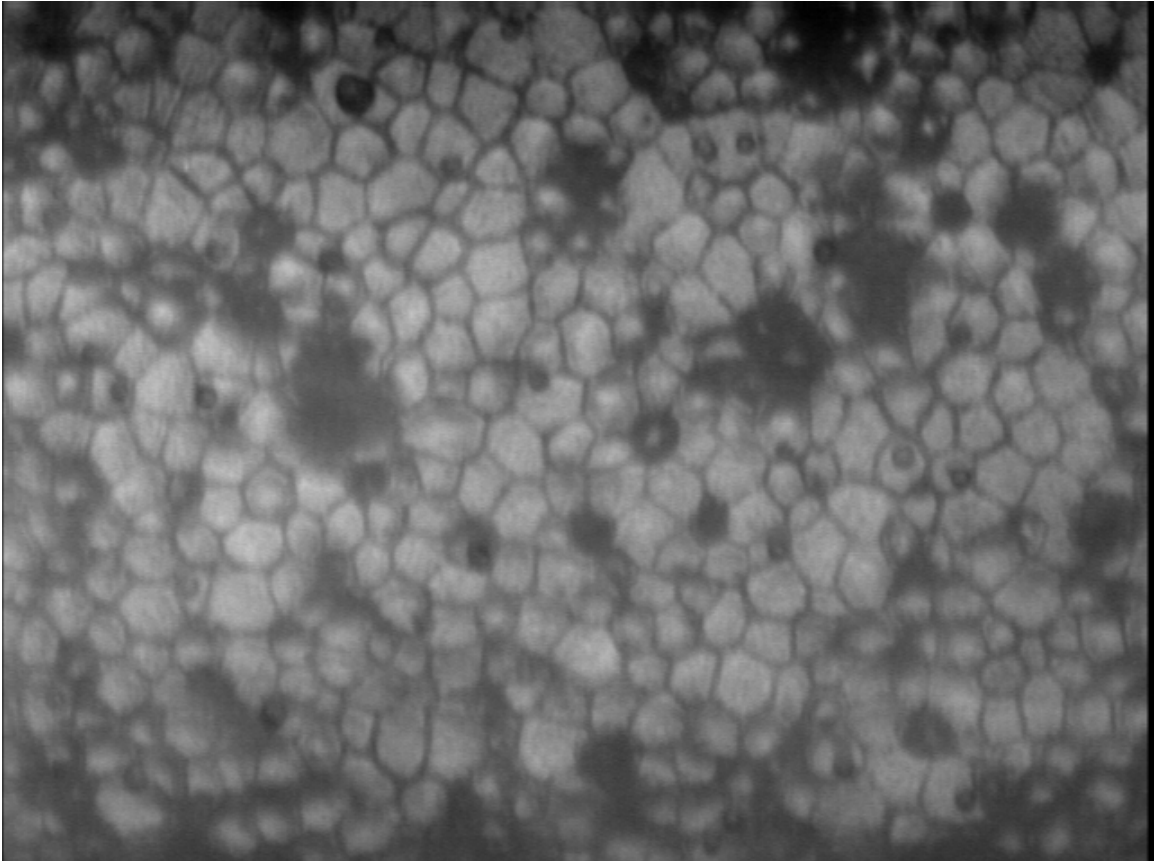
12a. Snail tracks (forceps trauma)



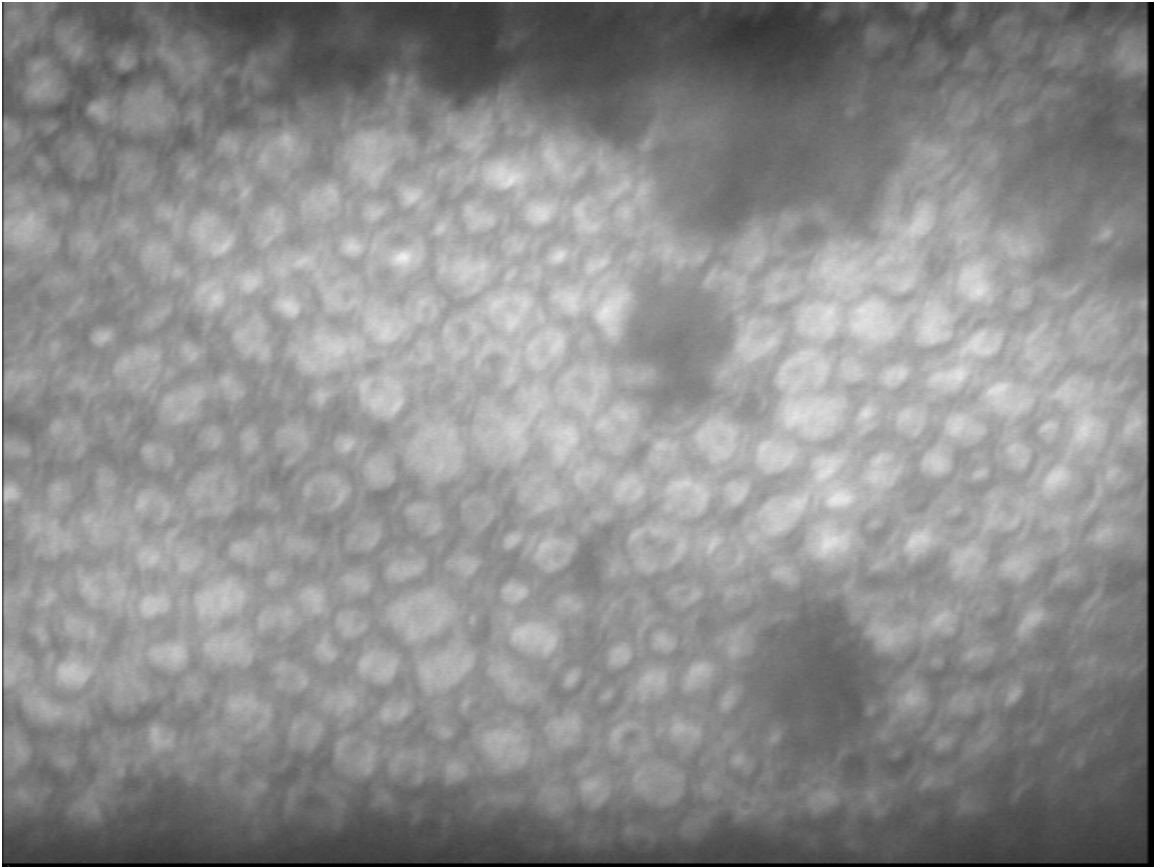
12b. Snail tracks (forceps trauma)



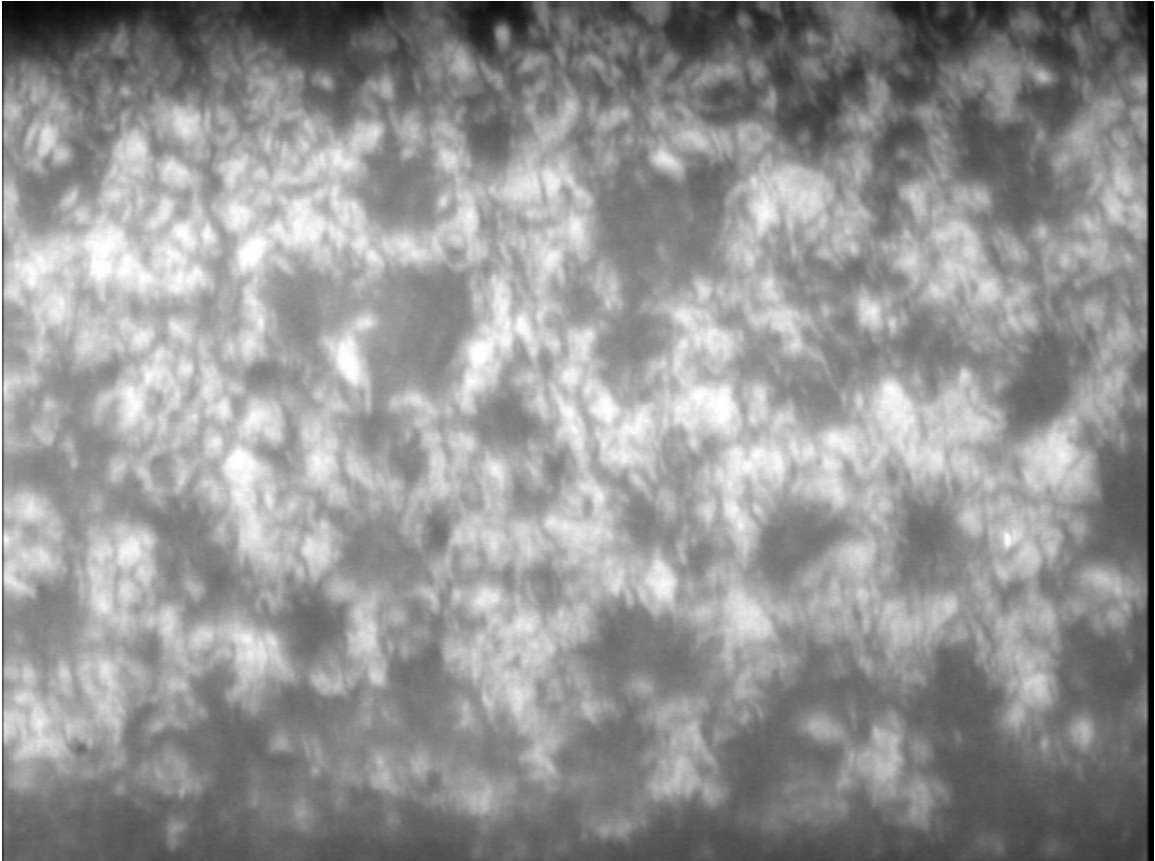
13a. Corneal guttata



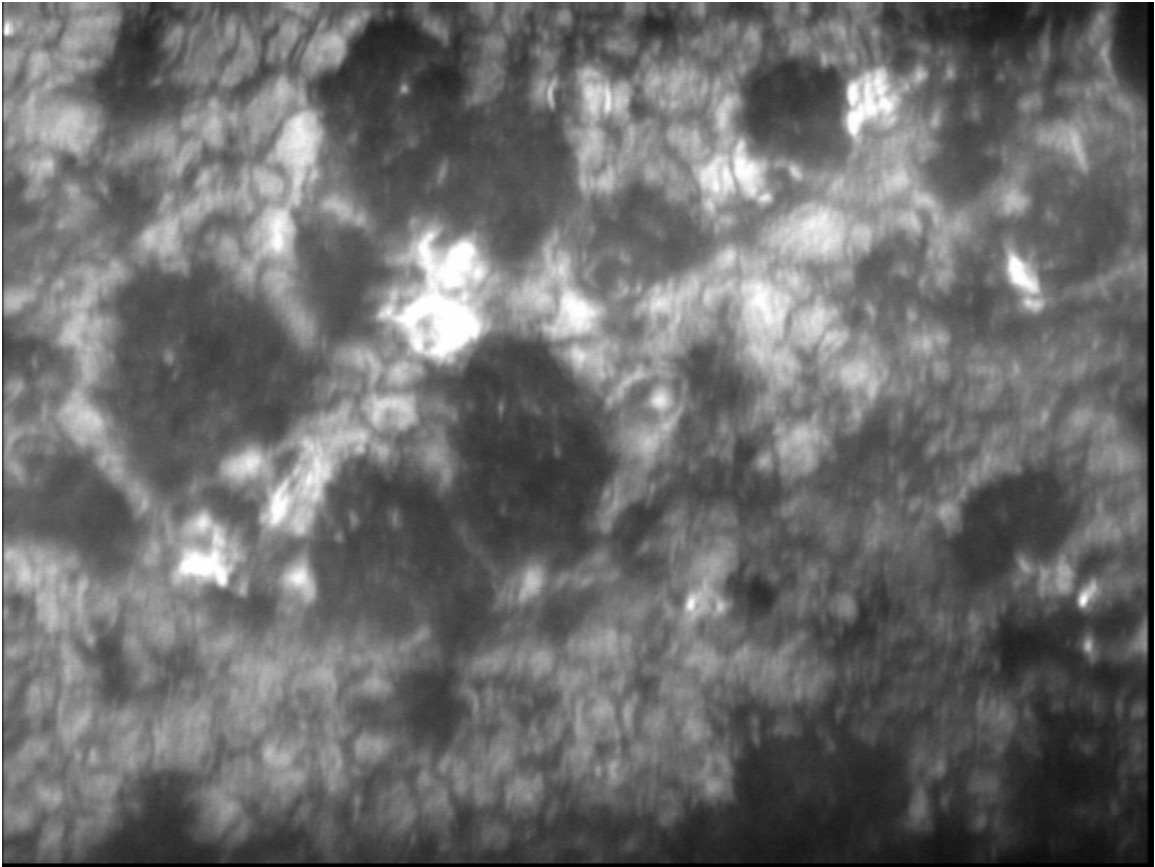
13b. Corneal guttata



14. Early-stage dystrophy




15a. Dystrophy



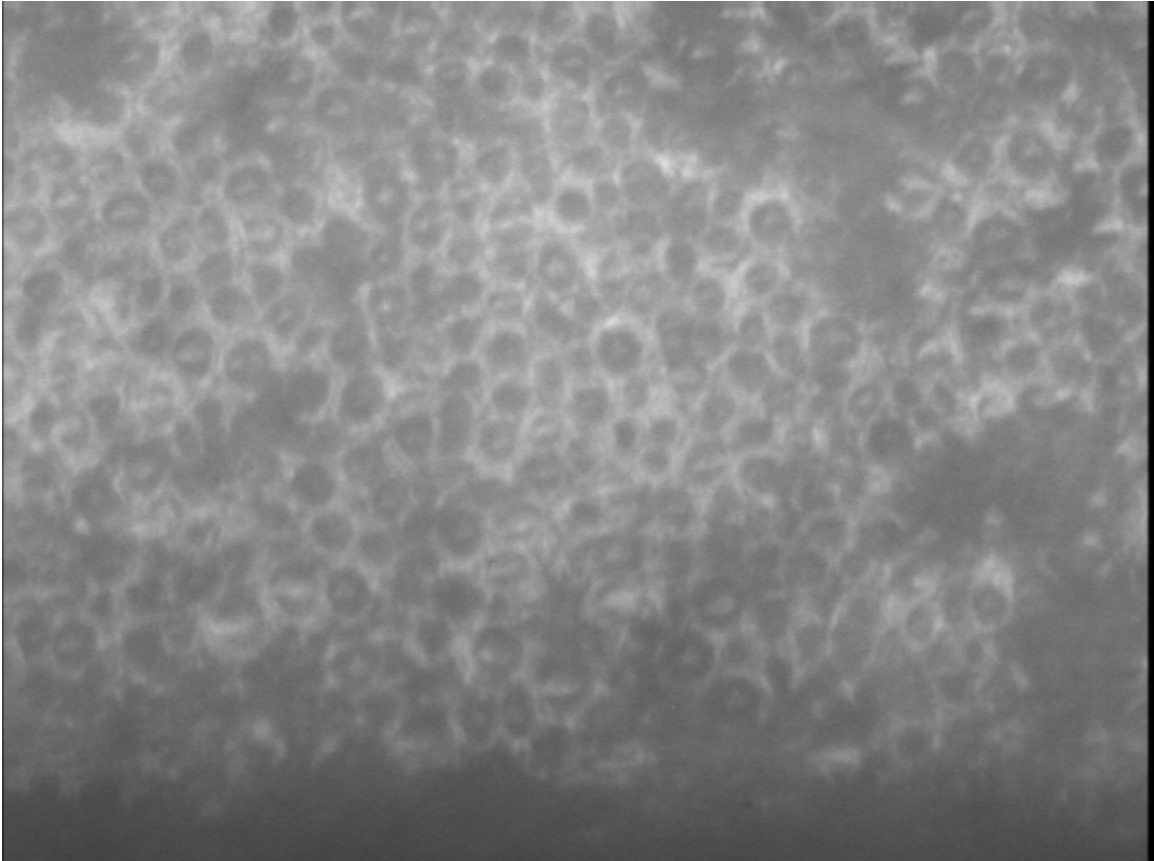
15b. Dystrophy



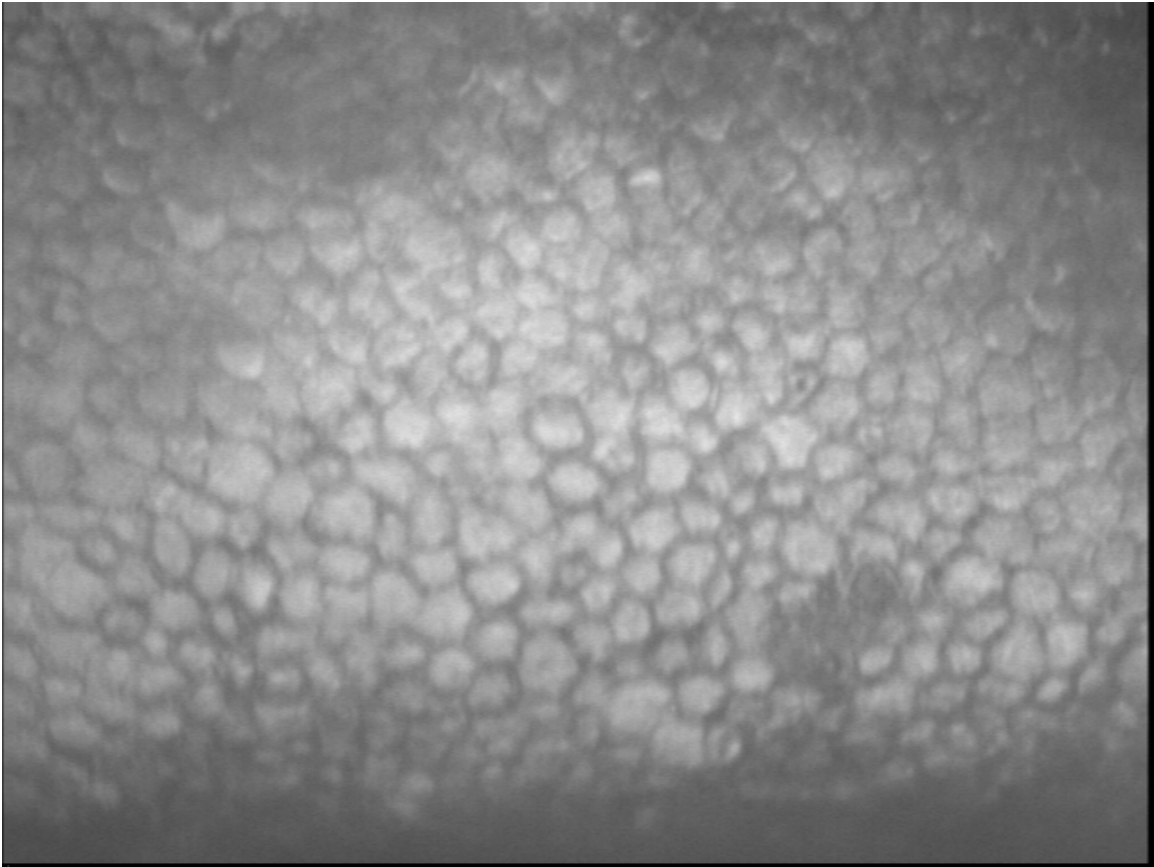
16. Severe dystrophy



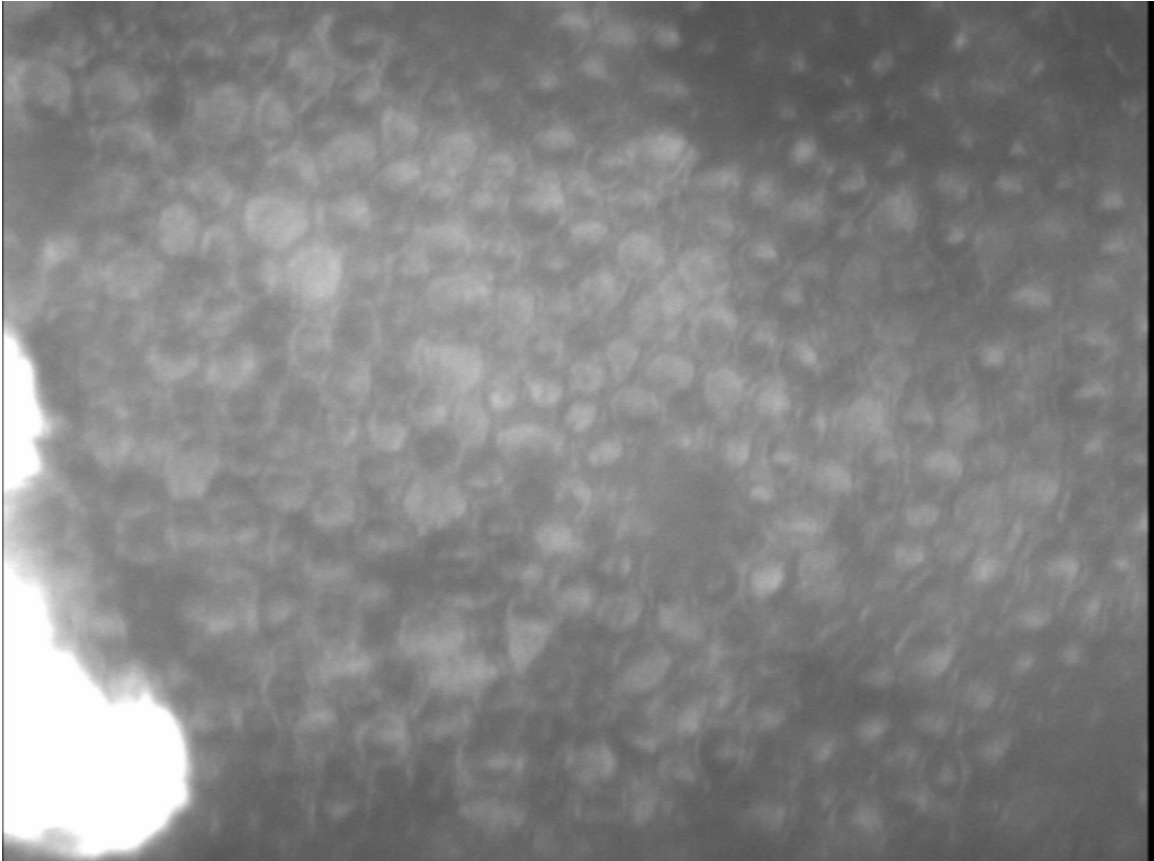
17a. Reverse cells (cause unknown)



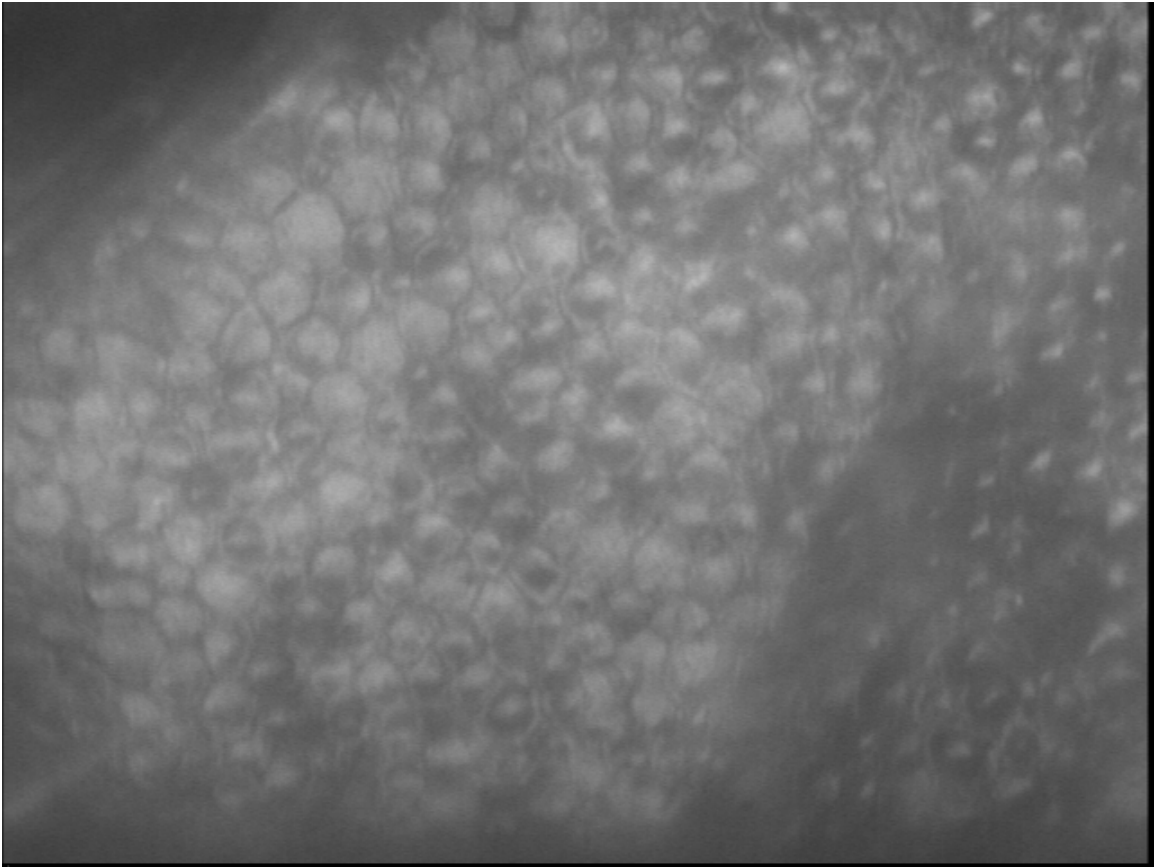
17b. Reverse cells (cause unknown)



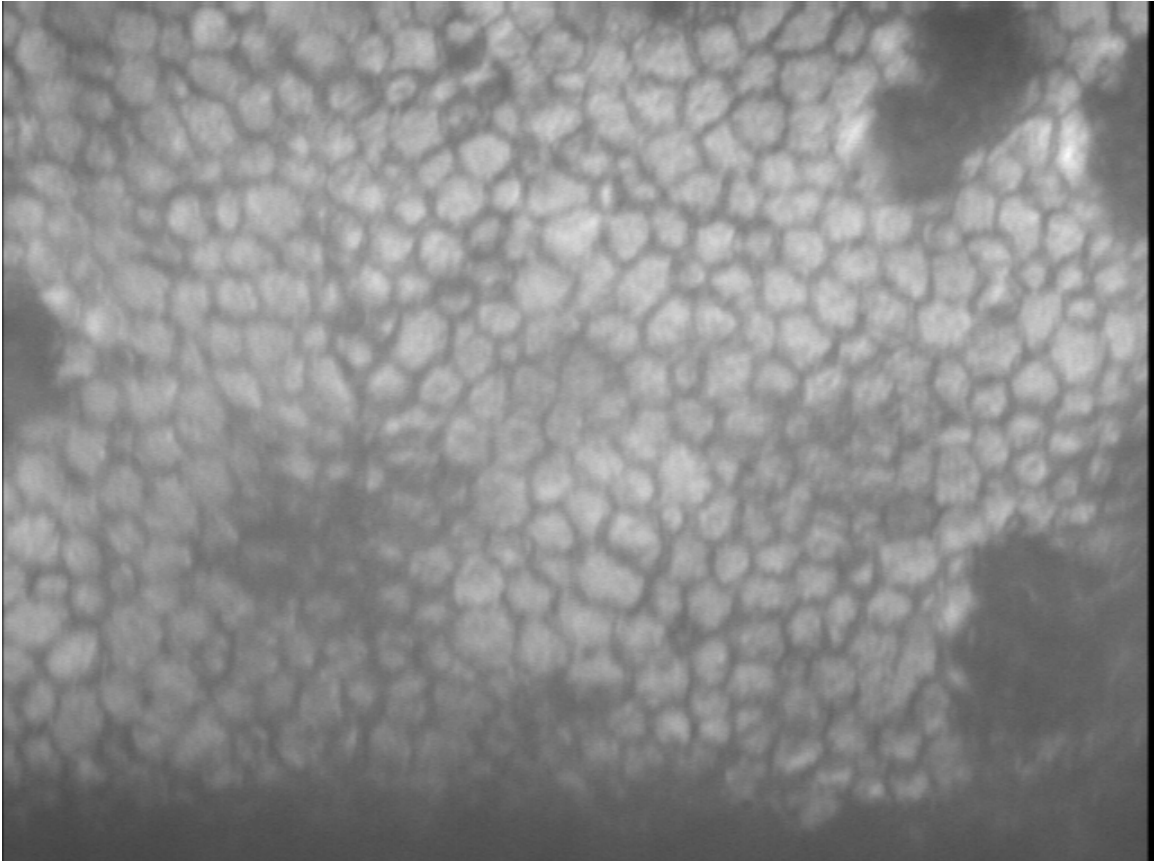
18. Post-cut cornea, mild folding



19a. Post-cut cornea, mild swelling



19b. Post-cut cornea, mild swelling



20. Post-cut cornea